

# LESSONS ALL CATARACT SURGEONS CAN LEARN FROM THE DEVELOPING WORLD

Innovative and counterintuitive thinking can help to address the most challenging problems.

By David F. Chang, MD

NEPAL

SOUTHERN INDIA



Cataract surgeons in the developing world must surmount countless obstacles beyond just getting trained—lack of equipment, lack of government funding for eye care, limited quantities of surgical supplies, and a shortage of competent ancillary help. However, the greatest challenge, which would undoubtedly overwhelm most of us in the developed world, is the huge backlog of advanced, mature cataracts in patients with multiple ocular comorbidities, including trauma, corneal scarring, glaucoma, zonulo-pathy, and diabetic retinopathy.

From a personal standpoint, observing these hardships has given me a greater appreciation for my own work environment and tremendous admiration for our dedicated colleagues who toil in such resource-poor settings.

I have long felt that our single greatest challenge in ocular surgery is the rapidly increasing backlog of cataract blindness in the developing world, which accounts for half of all global blindness.<sup>1</sup> This is hard for us to remember while preoccupied with that angry patient who still needs reading glasses despite his or her multifocal IOLs. Fortunately, some inspiring work is being done at places such as the Tilganga Eye Center in Kathmandu, Nepal, and the Aravind Eye Care System (AECS) in Southern India. I have had the great honor of learning from colleagues at both of these centers, where approximately 60% of all cataract surgeries are performed on charity patients. Both centers have perfected a standardized, assembly-line method of doing high-volume, low-cost cataract surgery at rates often exceeding 10 cases per hour per surgeon (Figures 1 and 2). To me, these are the most amazing eye surgical teams in the world, and it is a marvel to observe this surgical choreography in action.

## SIGNIFICANT LESSONS

I have also had the good fortune to collaborate with talented surgeons from Aravind and Tilganga on unique studies (Figure 3). Perhaps unexpectedly, these studies bear important and significant lessons for all cataract surgeons, which I highlight herein.

## LESSON 1 Manual small-incision cataract surgery may be safer for mature cataracts.

One of my early experiences doing phacoemulsification in a developing country was in 2005, when we conducted a randomized, prospective trial to compare phacoemulsification, as performed by me (Figure 4), with sutureless manual smallincision cataract surgery (MSICS), as performed by the leading Nepalese surgeon, Sanduk Ruit, MD (Figure 5).<sup>2</sup> MSICS uses a long, temporal, scleral-pocket incision that is tunneled wide enough to enable manual extraction of the undivided nucleus with an irrigating Simcoe cannula (Figure 6).<sup>3</sup> After a PMMA IOL is implanted, the incision is self-sealing without sutures and is largely astigmatically neutral due to its sutureless construction and temporal location. Most important, these advantages are achieved with a low-tech method on exceptionally dense, mature cataracts. Aside from the microscope and the sterilizer, none of the manual instrumentation requires electricity.



## AT A GLANCE

Strategies used by cataract surgeons in the developing world provide insight into first-world practices.

1. Manual small-incision cataract surgery may be safer for mature cataracts.
2. A squared posterior optic edge reduces posterior capsular opacification.
3. Intracameral moxifloxacin prophylaxis is safe and effective.
4. Many OR regulations may unnecessarily increase cost without proven benefit.

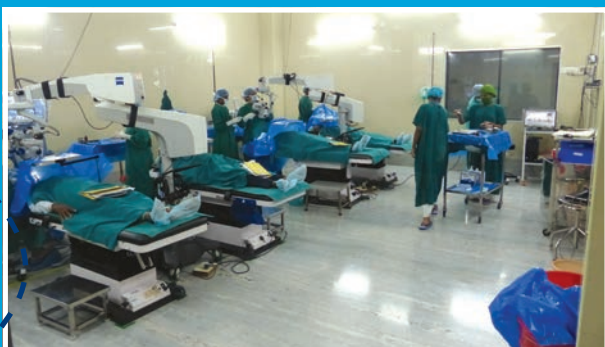

Figure 1. One OR at the Aravind hospital in Madurai. Two surgeons alternate between two adjacent operating beds by swinging the microscope from one table to the other.

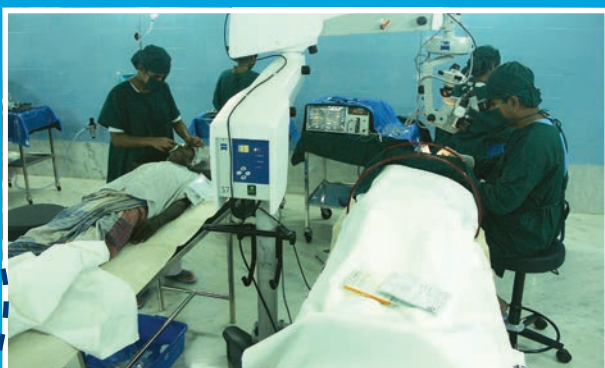

Figure 2. Rengaraj Venkatesh, MD, (Aravind Pondicherry) operating on one patient while his prior patient is patched. The next patient will be brought onto the adjacent bed and prepped so that Dr. Venkatesh can immediately commence the next surgery without delay.

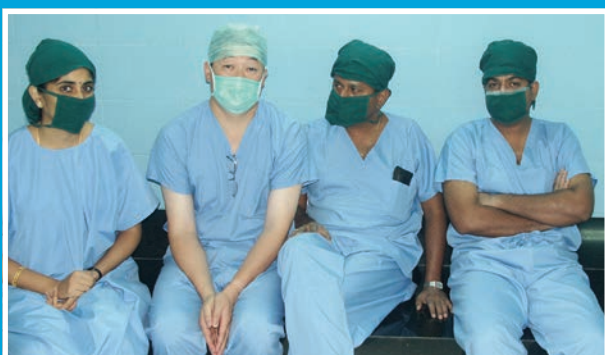

Figure 3. From left to right: Aravind Haripriya, MS, cochief of Aravind Chennai; the author; R. D. Ravindran, MS, DO, chief of Aravind Eye Care System; and Rengaraj Venkatesh, MD, chief of Aravind Pondicherry.

The study included a population of charity patients near Kathmandu, and we used classrooms in a Buddhist monastery as our makeshift ORs (Figure 7). The patients were monitored for 1 year, and we showed that distance UCVA and distance BCVA outcomes were equal between MSICS and phacoemulsification throughout the study period using the World Health Organization's criterion of 20/60 for functional vision.<sup>2</sup> Although outcomes and complication rates were comparable, MSICS was much faster and much less expensive to perform and resulted in faster visual recovery.

I was struck by the tremendous difficulty of doing phacoemulsification when the majority of cataracts were white or ultrabrunescent, the corneas were often scarred from trachoma, and the poor tear film and ocular surface so often marred my surgical view. I concluded that, for the many mature cataracts in this population, most Western surgeons and I would have a much higher complication rate with phacoemulsification than with MSICS.

In subsequent studies, including one of 79,777 consecutive cataract surgeries performed at the Aravind hospital in Madurai, India, we were able to show that, in experienced hands, both phacoemulsification and MSICS had comparably low surgical complication rates of approximately 1%.<sup>4,5</sup> However, for inexperienced surgeons and trainees, MSICS had a much lower rate of complications, such as posterior capsular rupture.<sup>5</sup> Avoiding retained nuclear fragments is crucial in the many developing countries where there may be no access to a vitreoretinal surgeon. We concluded that, to train new cataract surgeons in underserved societies, MSICS should initially be the procedure of choice.

In my own practice, I resort to MSICS for the densest cataracts when I feel that comorbidities such as a crowded anterior segment, zonulopathy, corneal opacity, or severe miosis may make phacoemulsification the riskier procedure for the endothelium or posterior capsule. It is a wonderful option to have in my surgical armamentarium.

**LESSON 2** A squared posterior optic edge reduces posterior capsular opacification regardless of IOL material. To reduce cost, PMMA IOLs are typically used in conjunction with the large MSICS incision, but they have been associated with

higher rates of posterior capsular opacification (PCO). PCO is an inconvenience for patients in developed countries, but in the developing world, where follow-up eye care or an Nd:YAG laser may not be accessible, it is a leading cause of visual impairment. Our prospective, bilateral eye study at the Aravind hospital in Madurai randomized implantation of a round-edged PMMA IOL in one eye and a square-edged PMMA IOL in the other.<sup>6</sup> Using digital retroillumination image analysis over 9 years of follow-up, we showed that, with the round-edged optics, the PCO rate did not level off but continued to climb. The square-edged PMMA

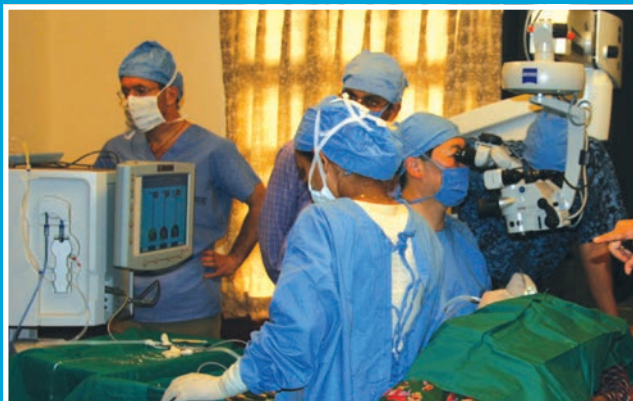

Figure 4. The author performing phacoemulsification within a makeshift OR at the Pulihari Monastery in Nepal, 2005.

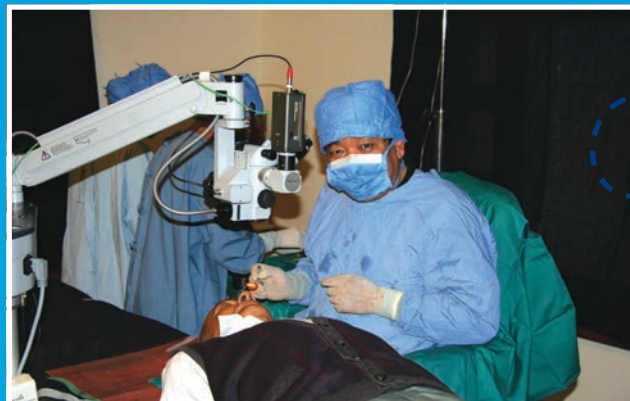

Figure 5. Dr. Ruit performing MSICS within a makeshift OR at the Pulihari Monastery in Nepal, 2005.

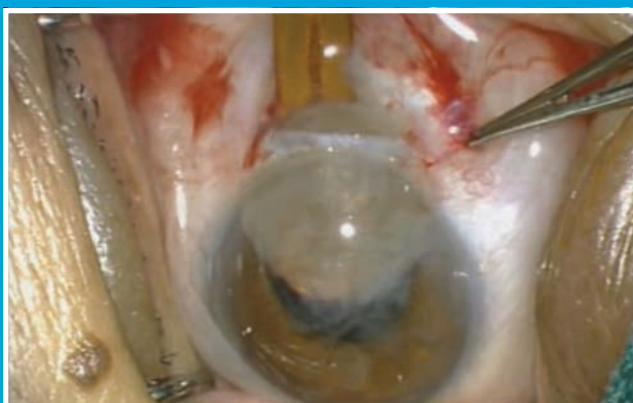

Figure 6. Dr. Ruit performing MSICS on a white cataract using an irrigating cannula.



Figure 7. Postoperative cataract patients in Nepal.



Figure 8. The author and Dr. Haripriya in Madurai, India, 2015.



Figure 9. The author and Dr. Ruit in Kathmandu, Nepal, 2005.

IOLs we used significantly prevented PCO, and they were even statistically superior to square-edged AcrySof foldable IOLs (Alcon) used in a separate, parallel 9-year study.<sup>6</sup>

This is the longest-term bilateral eye study prospectively comparing the impact of IOL edge design on PCO published to date. It demonstrated that this inexpensive edge modification, costing approximately \$1 per IOL, might

markedly reduce a major cause of visual impairment in developing countries.


**LESSON 3** Intracameral moxifloxacin prophylaxis is safe and effective. Because of the expense and difficulty of performing a randomized controlled trial, some of the best evidence on endophthalmitis

prophylaxis has come from large retrospective studies. Our recent study of charity patients at the Aravind hospital in Madurai compared 37,777 consecutive surgeries without an intracameral (IC) antibiotic to 38,160 consecutive surgeries with IC moxifloxacin prophylaxis over a 14-month period.<sup>7</sup> Nearly all surgeries (97%) were performed with the MSICS technique.

AECS's affiliated pharmaceutical company, Aurolab, manufactures a moxifloxacin solution commercially approved for intraocular use in India (Auromox), and one \$1 vial is used for five patients. The use of a single \$0.20 dose of IC moxifloxacin reduced the endophthalmitis rate from 0.08% in those who did not receive the IC drug to 0.02% in those who did.

We believe an IC antibiotic should be used, if available, when MSICS is employed in the developing world. We recently published additional data from 617,453 consecutive phaco and MSICS cases performed at all 10 regional AECS hospitals over a 29-month period.<sup>8</sup> IC moxifloxacin reduced the endophthalmitis rate from 0.07% in the 302,815 cases without an antibiotic to 0.02% in the 314,638 cases with an antibiotic. In a follow-up correspondence, we will soon report an identical infection rate reduction with IC moxifloxacin in more than 1 million consecutive eyes over a 4-year period. These are the largest published efficacy data for IC moxifloxacin prophylaxis, and they are the basis for my use of compounded IC moxifloxacin in my own cataract patients.

**LESSON** **Many OR regulations may unnecessarily increase costs without proven benefit.** At one time, one of the main OR regulatory agencies in the United States began mandating a full, wrapped terminal sterilization cycle for eye surgical instruments for every case. There was no published evidence to validate that commonly used shorter steam sterilization cycles were safe and effective. A subsequently published study of more than 42,000 consecutive cases at the Aravind hospital in Pondicherry was a key article used to substantiate the safety of shorter cycle sterilization of ophthalmic instruments in the United States.<sup>9</sup> This study also documented a low endophthalmitis rate of 0.09% despite the reuse of gowns, gloves, surgical tubing, irrigating solutions, and a number of instruments and drugs limited to single use in the United States. Another concern with reuse of instruments is the risk of toxic anterior segment syndrome (TASS). Our study at the Aravind hospital in Pondicherry found the rate of TASS to be 0.22% in 26,408



consecutive eyes and included two identifiable clusters.<sup>10</sup> This is the only large study to report the sporadic incidence of TASS, and we reported a very low incidence of serious long-term complications.

As noted previously, charity patients account for 60% of AECS's cataract surgical volume. Therefore, maintaining safety and quality while reducing unnecessary costs and procedural steps is necessary to maximize surgical efficiency and access to those blinded by cataract. Surgeons at both AECS and Tilganga further improve efficiency by operating on multiple patients simultaneously in the same OR. Despite the use of innumerable OR practices that would never be permitted in the United States, the endophthalmitis rate in more than 528,000 consecutive cataract surgeries at the 10 AECS facilities following routine adoption of IC moxifloxacin is only 0.02%.<sup>8</sup>

## CONCLUSION

Low-tech MSICS through larger incisions, use of extremely low-cost IOLs and supplies, reuse of as many supplies as possible, and 10-case-per-hour assembly-line efficiency would be unthinkable practices in developed countries. However, solving the challenge of eradicating cataract blindness in the developing world requires innovative and sometimes counterintuitive thinking. The noble surgeons at AECS and Tilganga Eye Hospitals should be celebrated not only for their compassion, but also for the lessons that they can teach the rest of us (Figures 8 and 9). ■

1. Chang DF. Tackling the greatest challenge in cataract surgery [editorial]. *Br J Ophthalmol*. 2005;89(9):1073-1074.
2. Ruit S, Tabin G, Chang DF, et al. A prospective randomized clinical trial of phacoemulsification vs manual sutureless small incision extracapsular cataract surgery in Nepal. *Am J Ophthalmol*. 2007;143:32-38.
3. Venkatesh R, Chang DF, Muralikrishnan R, et al. Manual small incision cataract surgery: a review. *Asia Pac J Ophthalmol (Phila)*. 2012;1(2):113-119.
4. Venkatesh R, Tan CS, Sengupta S, et al. Phacoemulsification versus manual small-incision cataract surgery for white cataract. *J Cataract Refract Surg*. 2010;36:1849-1854.
5. HariPriya A, Chang DF, Reena M, Shekhar M. Analysis of complication rates of phacoemulsification and manual small-incision cataract surgery at Aravind Eye Hospital. *J Cataract Refract Surg*. 2012;38:1360-1369.
6. HariPriya A, Chang DF, Vijayakumar B, et al. Long-term posterior capsule opacification reduction with square-edge polymethylmethacrylate intraocular lens. *Ophthalmology*. 2017;124:295-302.
7. HariPriya A, Chang DF, Nambur S, et al. Efficacy of intracameral moxifloxacin endophthalmitis prophylaxis at Aravind Eye Hospital. *Ophthalmology*. 2016;123:302-308.
8. HariPriya A, Chang DF, Ravindran RD. Endophthalmitis reduction with intracameral moxifloxacin prophylaxis: analysis of 600,000 surgeries. *Ophthalmology*. 2017;124:768-775.9.
9. Ravindran RD, Venkatesh R, Chang DF, et al. The incidence of post-cataract endophthalmitis at an Aravind Eye Hospital: Outcomes from more than 42,000 consecutive cases using standardized sterilization and prophylaxis protocols. *J Cataract Refract Surg*. 2009;35:629-636.
10. Sengupta S, Chang DF, Gandhi R, et al. Incidence and long-term outcomes of toxic anterior segment syndrome at Aravind Eye Hospital. *J Cataract Refract Surg*. 2011;37:1673-1678.

### David F. Chang, MD

- clinical professor, University of California, San Francisco
- private practice, Los Altos, California
- [dceye@earthlink.net](mailto:dceye@earthlink.net)
- financial interest: none acknowledged